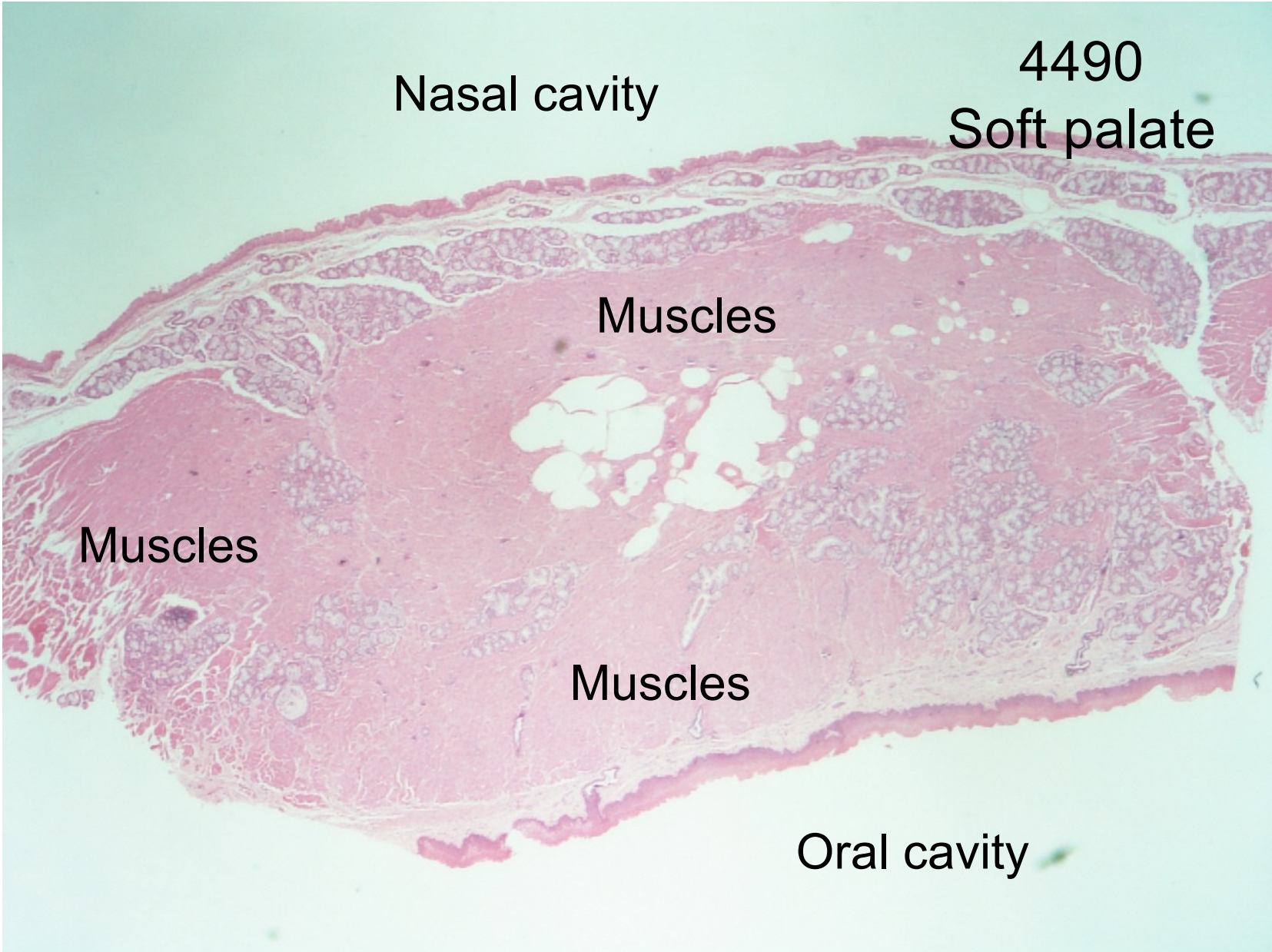

Nasal cavity

4490

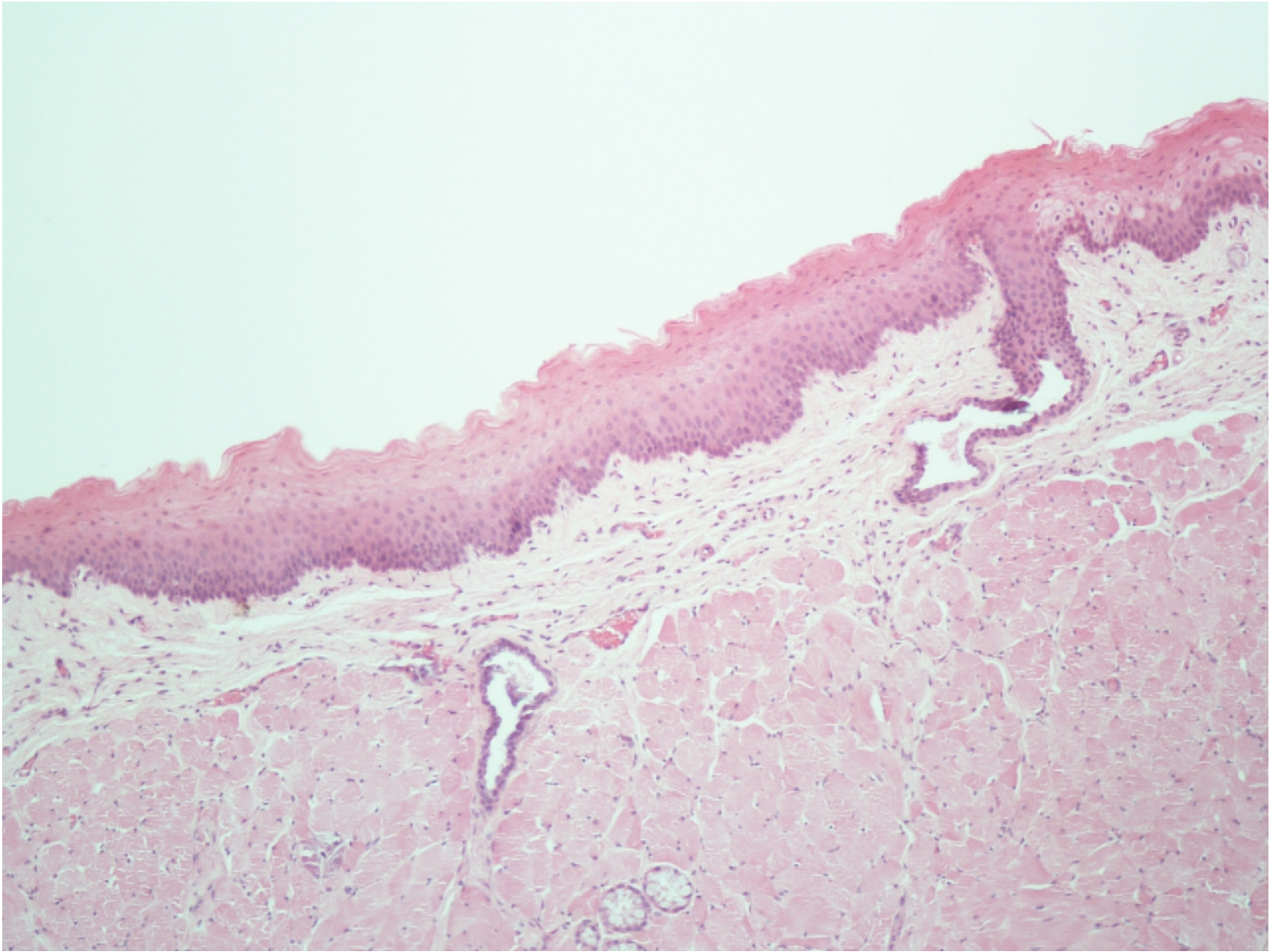
Soft palate

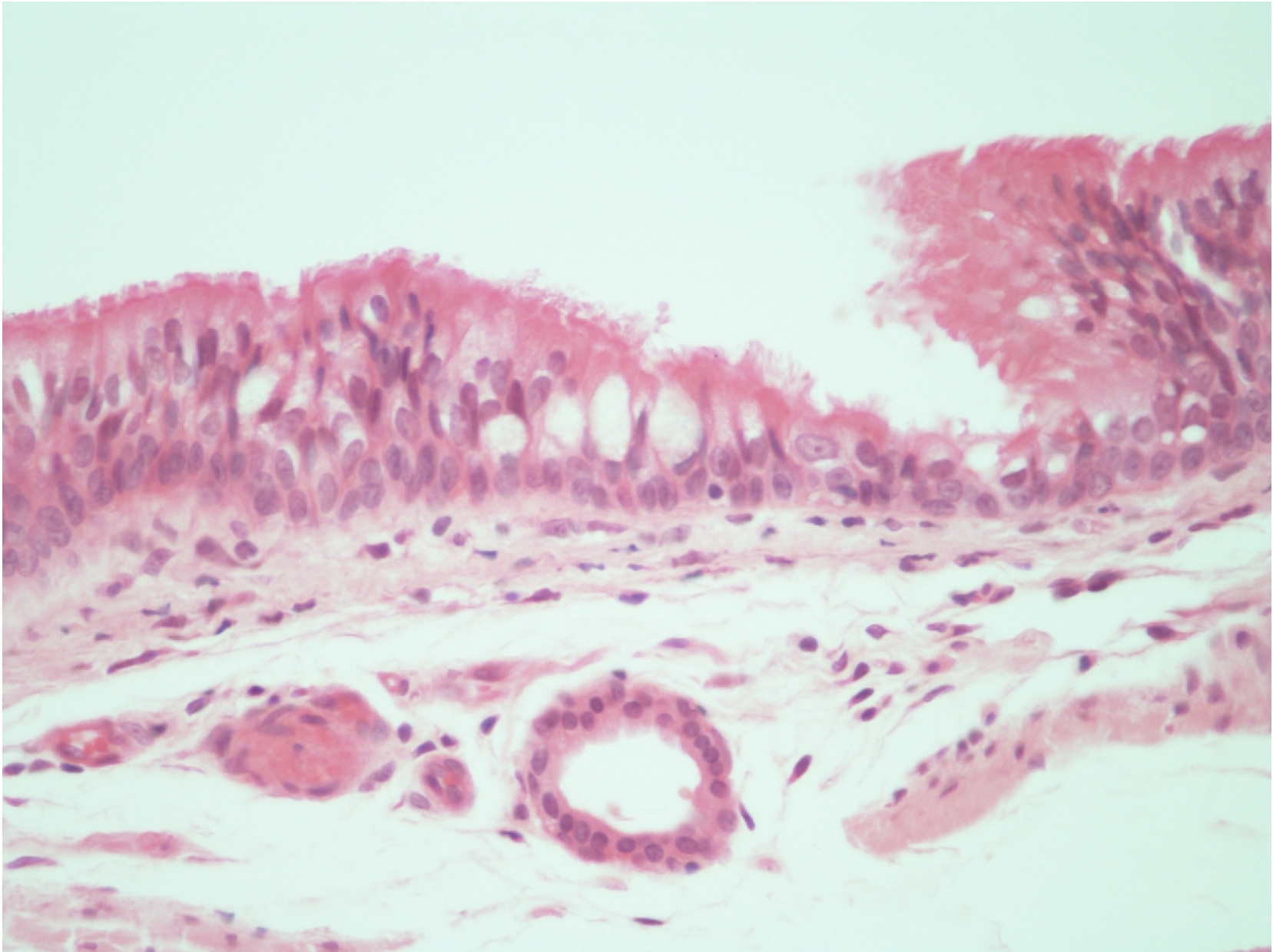
Muscles

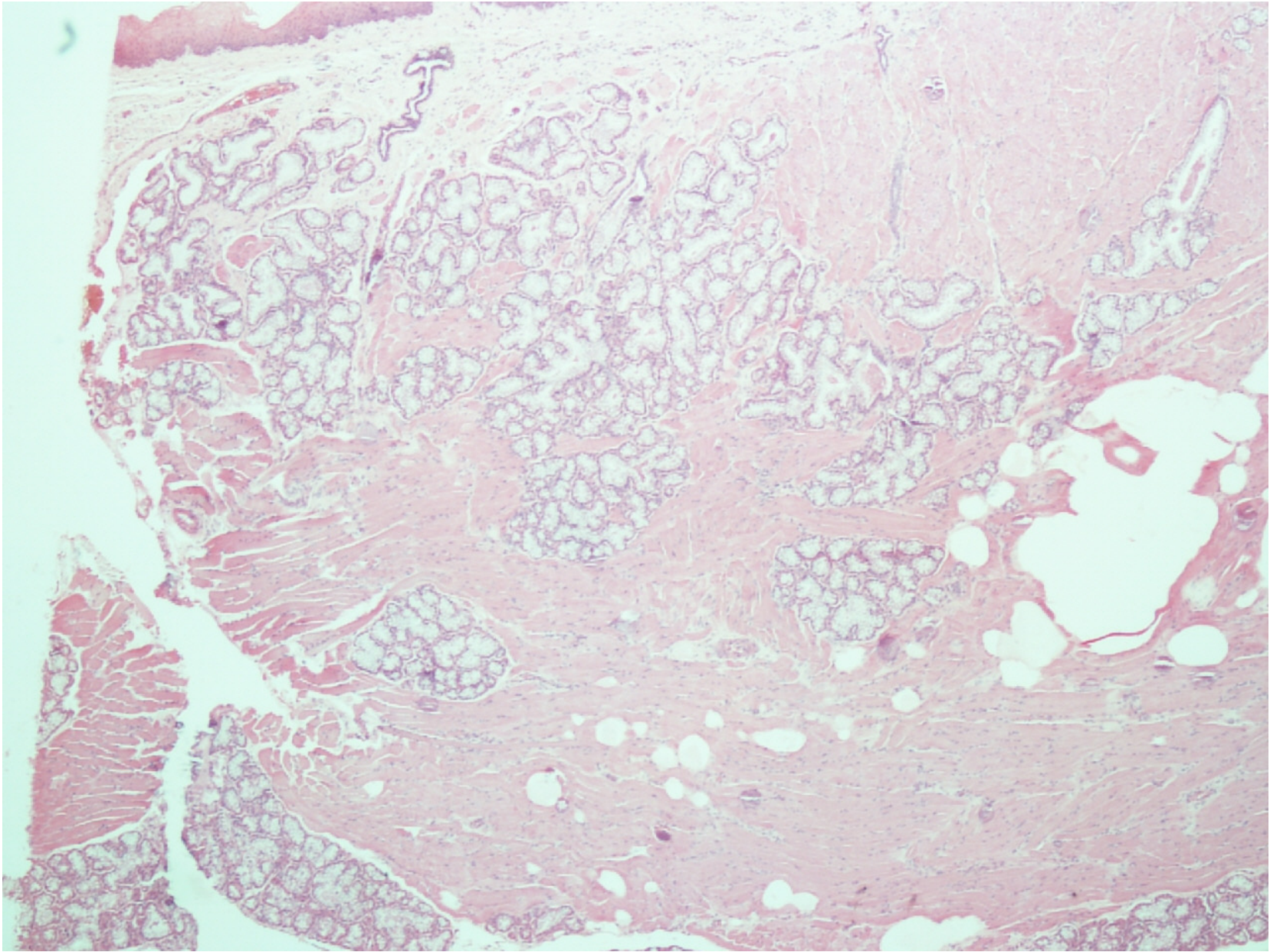
Muscles

Muscles

Oral cavity





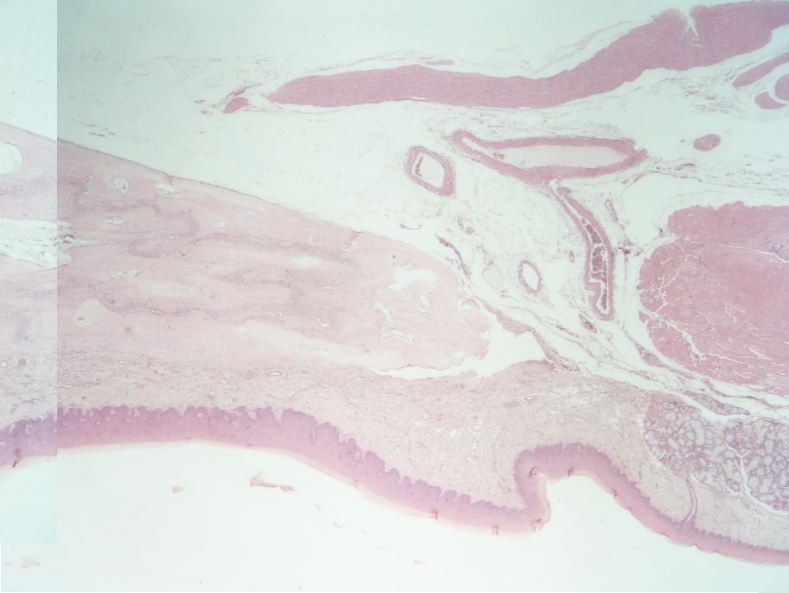


4494

Hard and soft palate



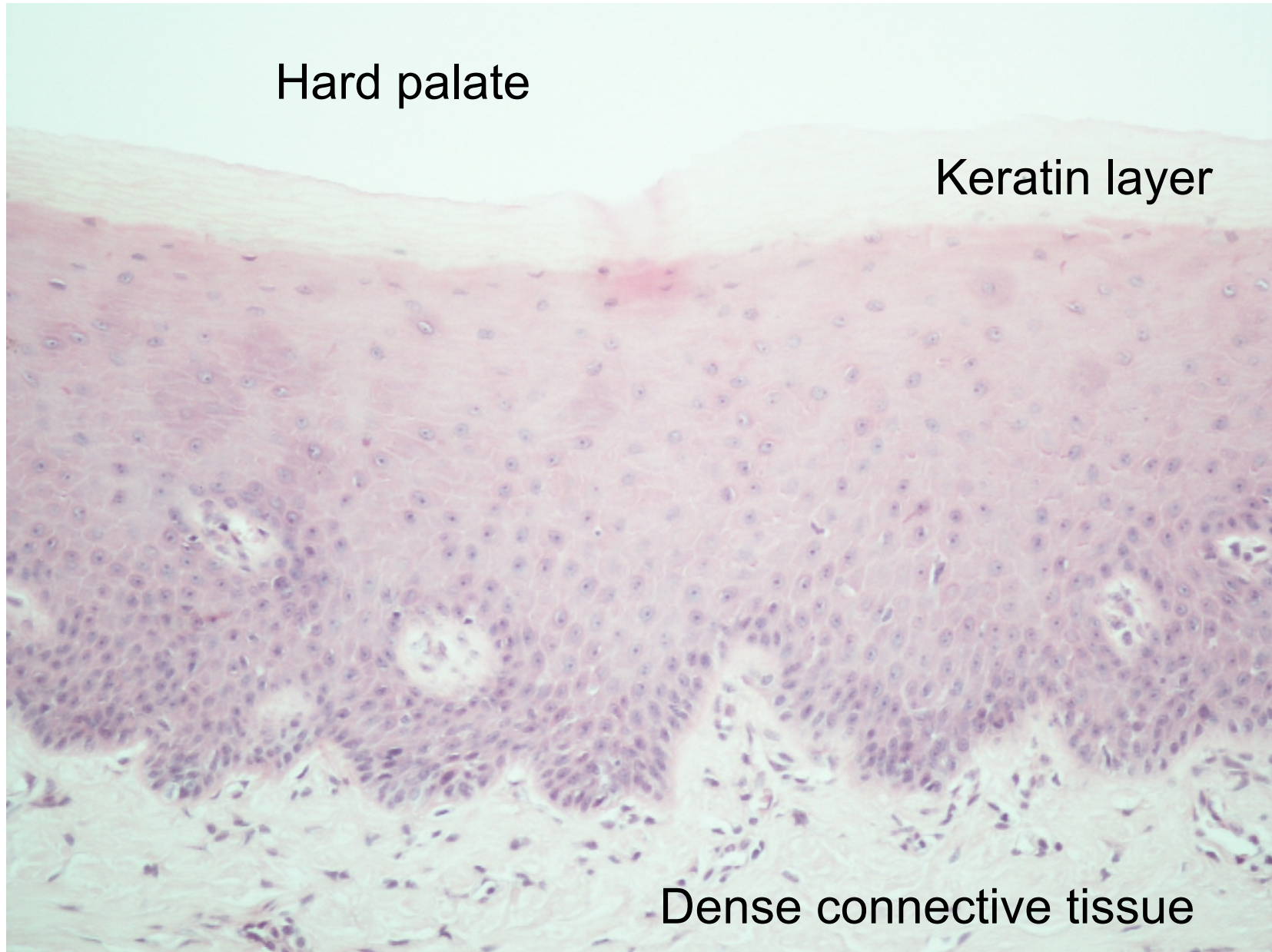
Hard palate



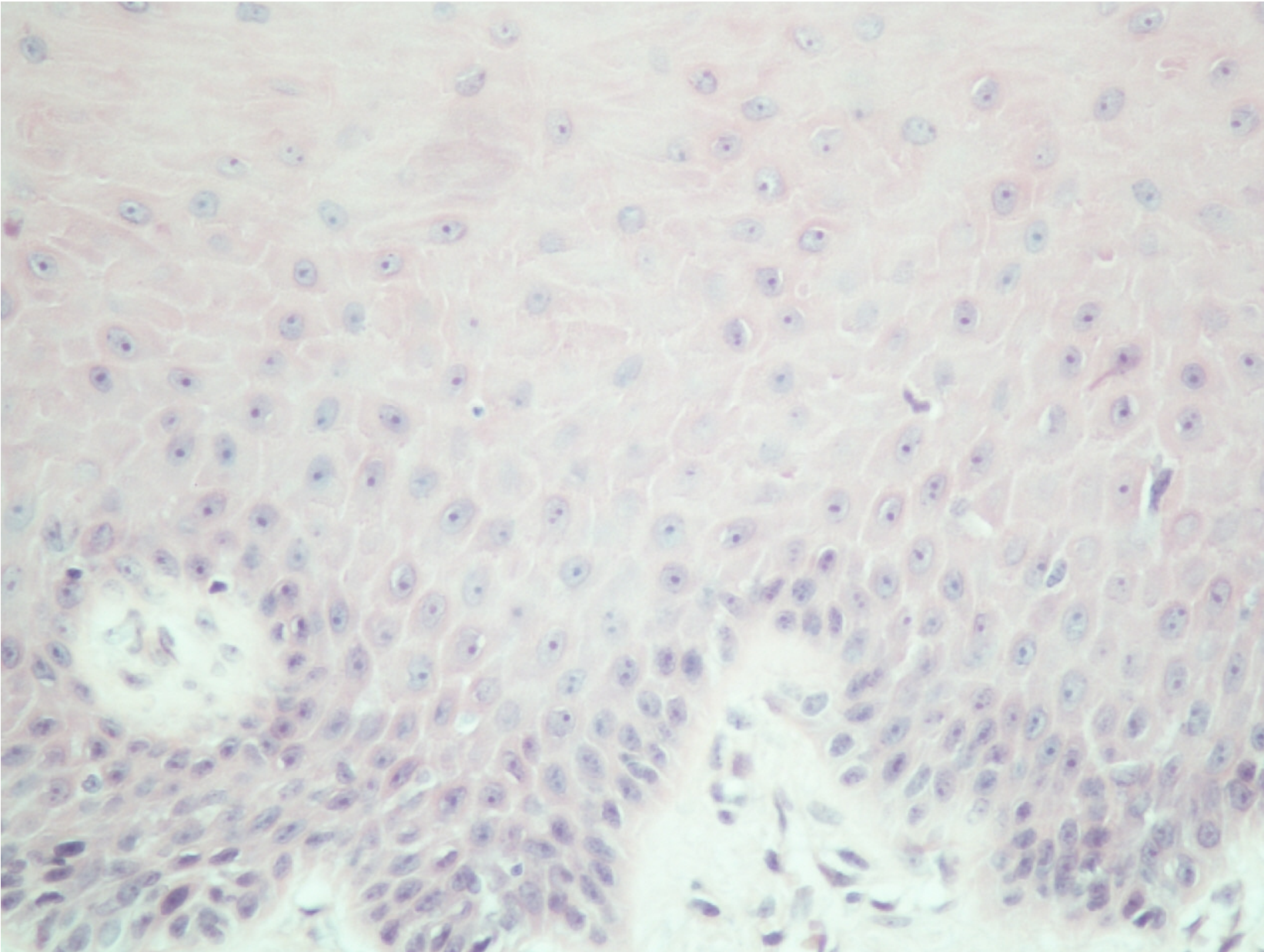
Muscles of
soft palate

Hard palate

Keratin layer



Dense connective tissue



Key point

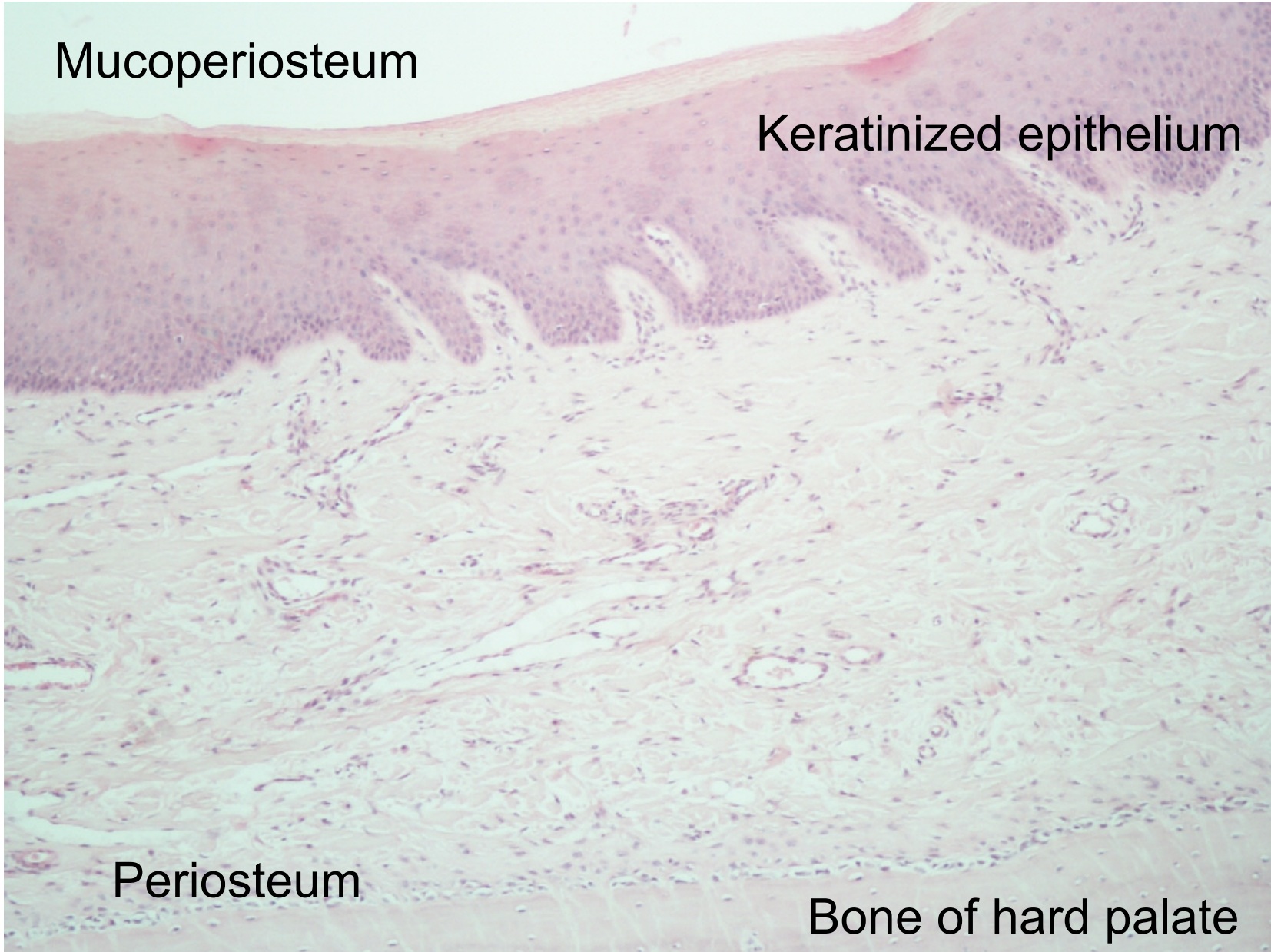
- Basal layer
- Prickle cell layer
- Clear cells
- Basement membrane

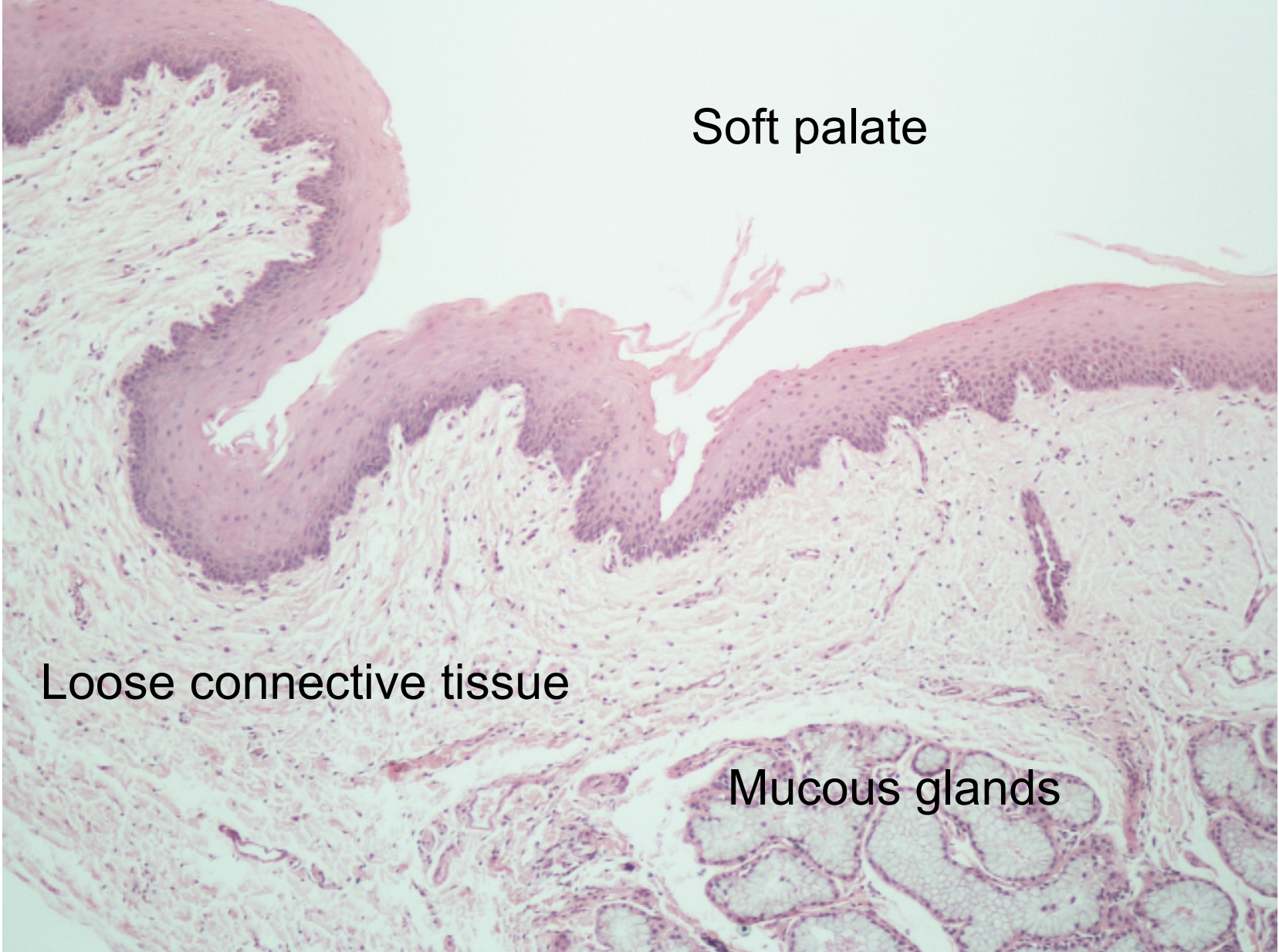
Mucoperiosteum

Keratinized epithelium

Periosteum

Bone of hard palate



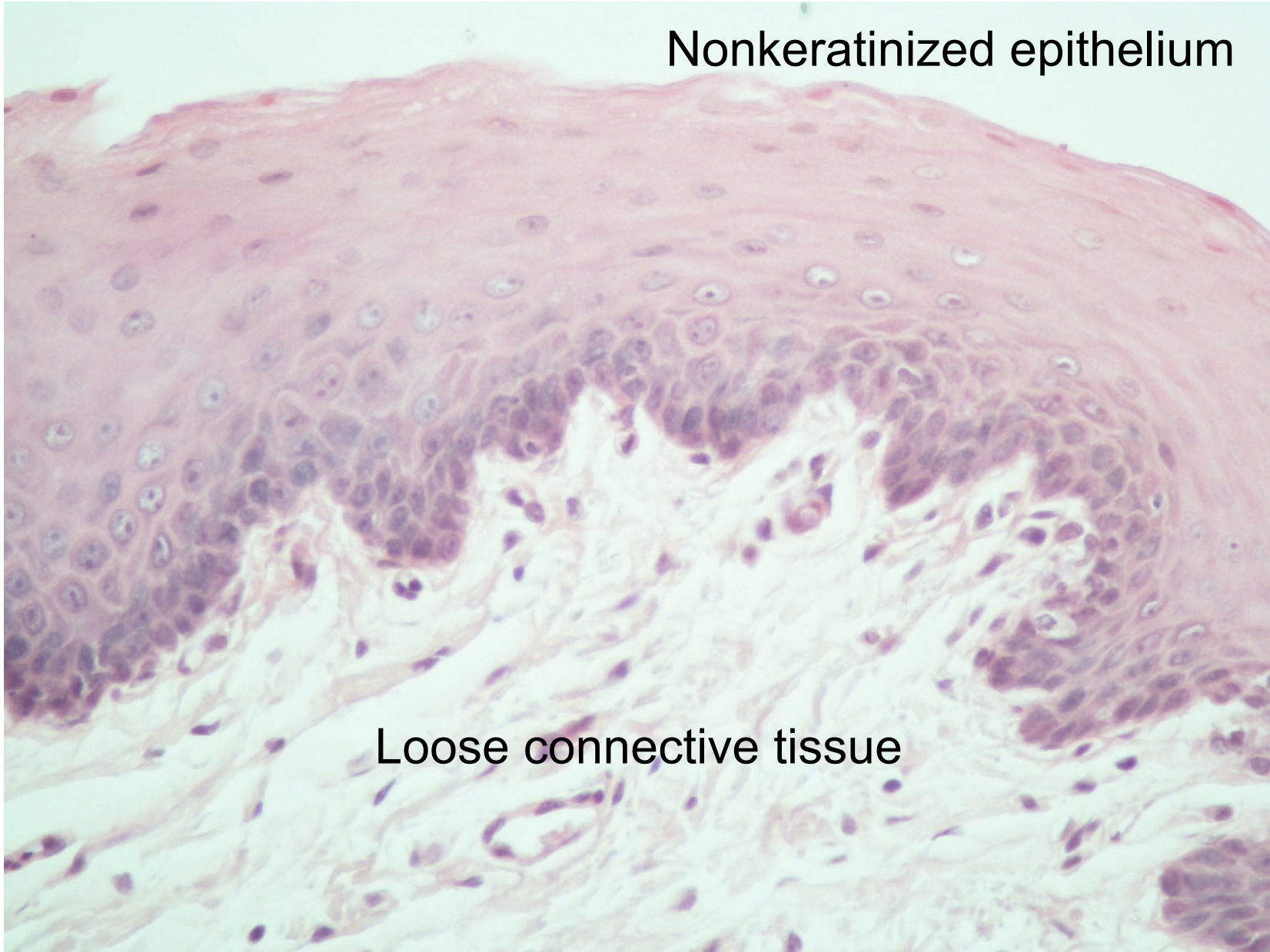


Soft palate

Loose connective tissue

Mucous glands

Nonkeratinized epithelium



Loose connective tissue

Comparison of keratinized and nonkeratinized mucosa

Key point

- 4 layers of the epithelium
- Connective tissue

