

Oral Embryology and Histology

H&E Section of Tooth

H090020

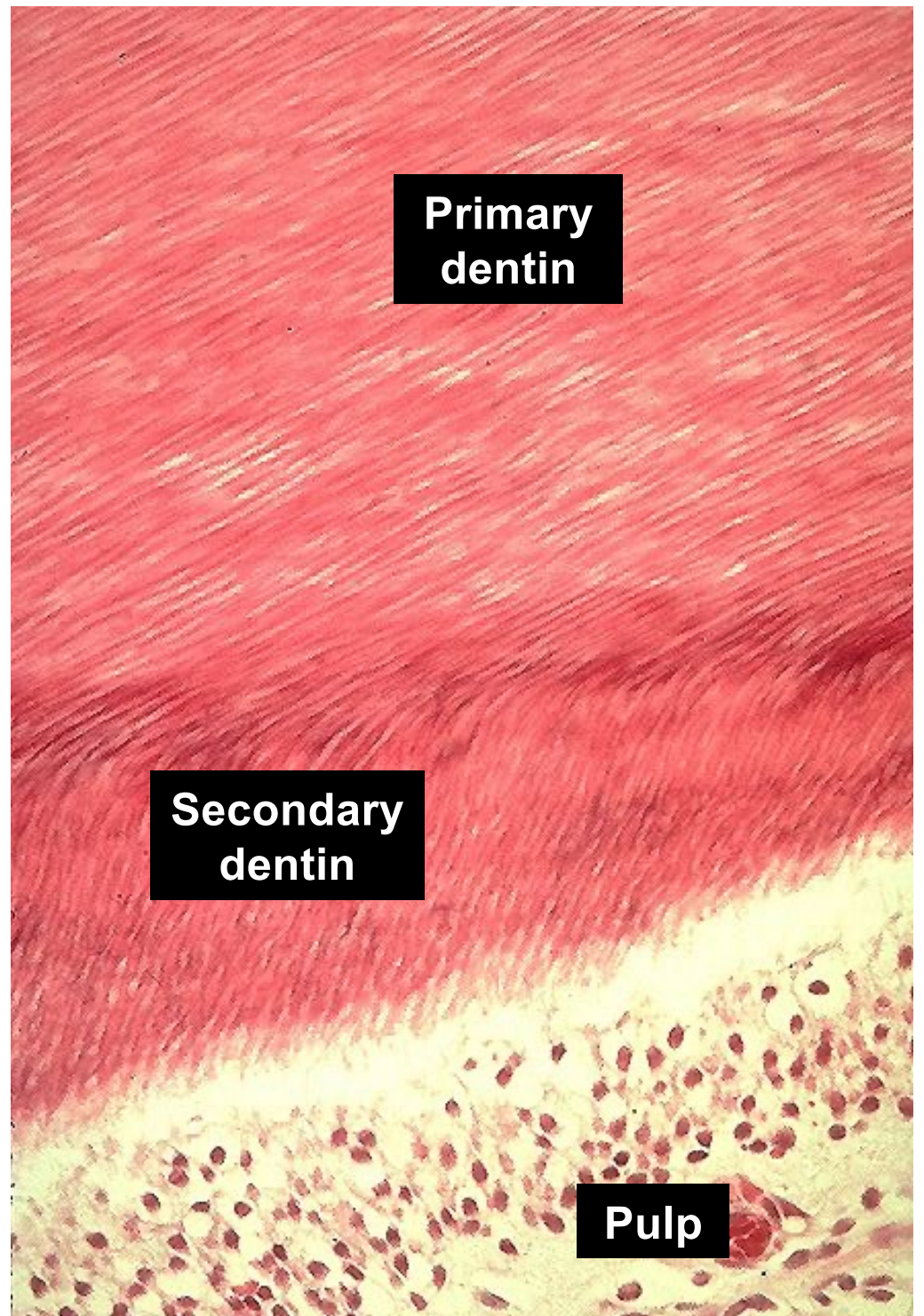
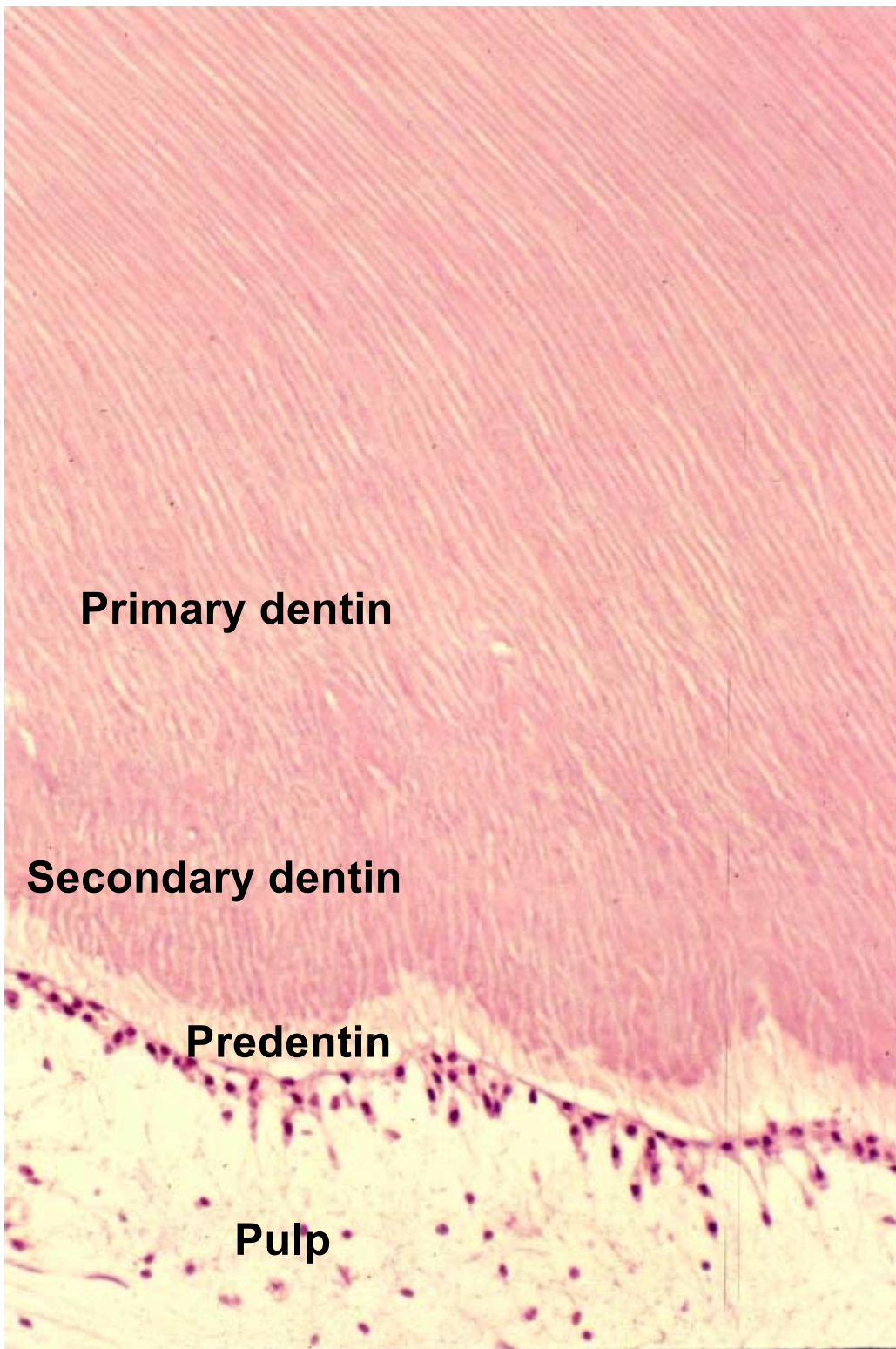



College of Oral Medicine
Chung Shan Medical University



Chuan-Hang Yu

E-mail: chuanhang2007@gmail.com

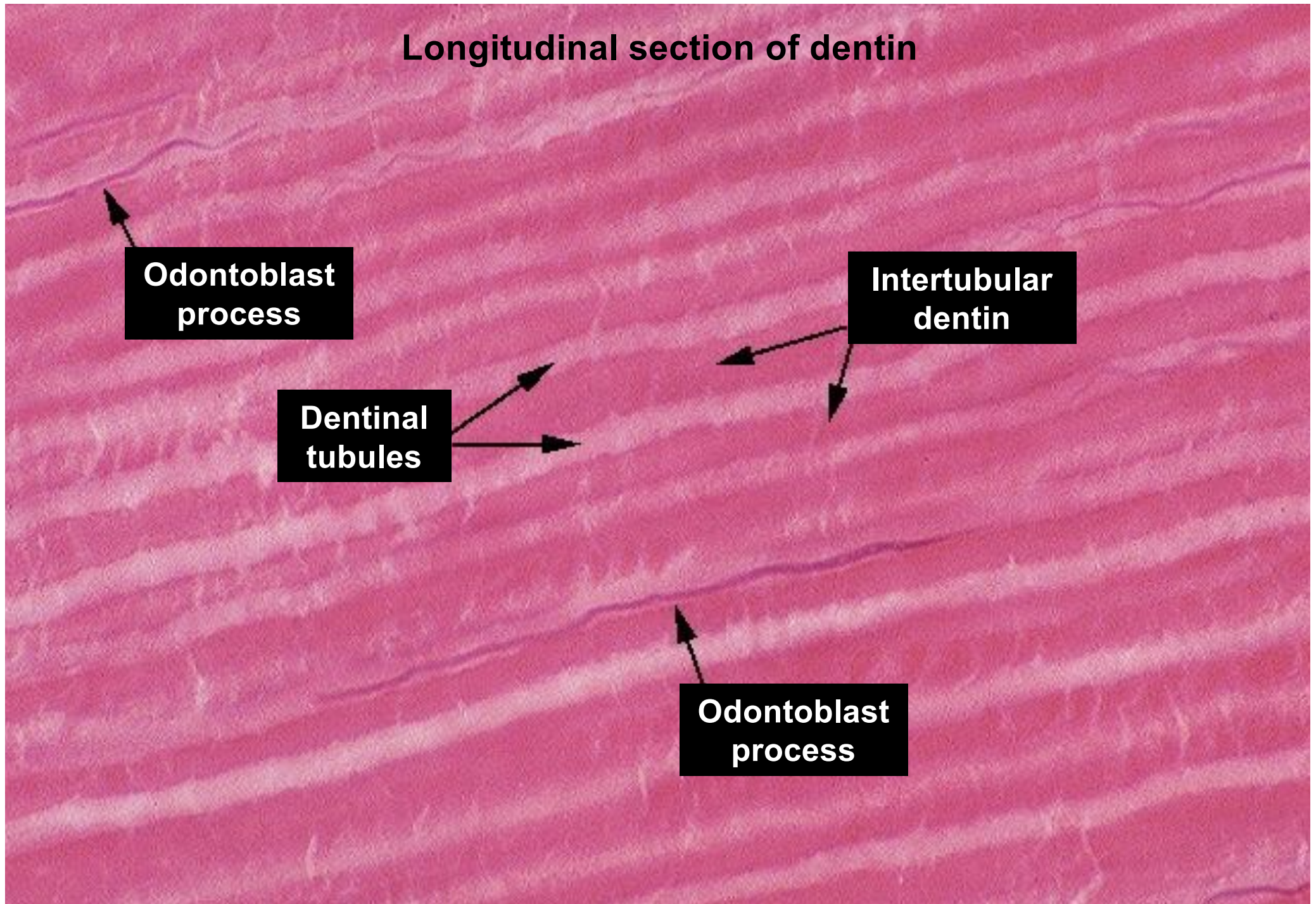




**Incremental lines
of von Ebner**

C

Longitudinal section of dentin



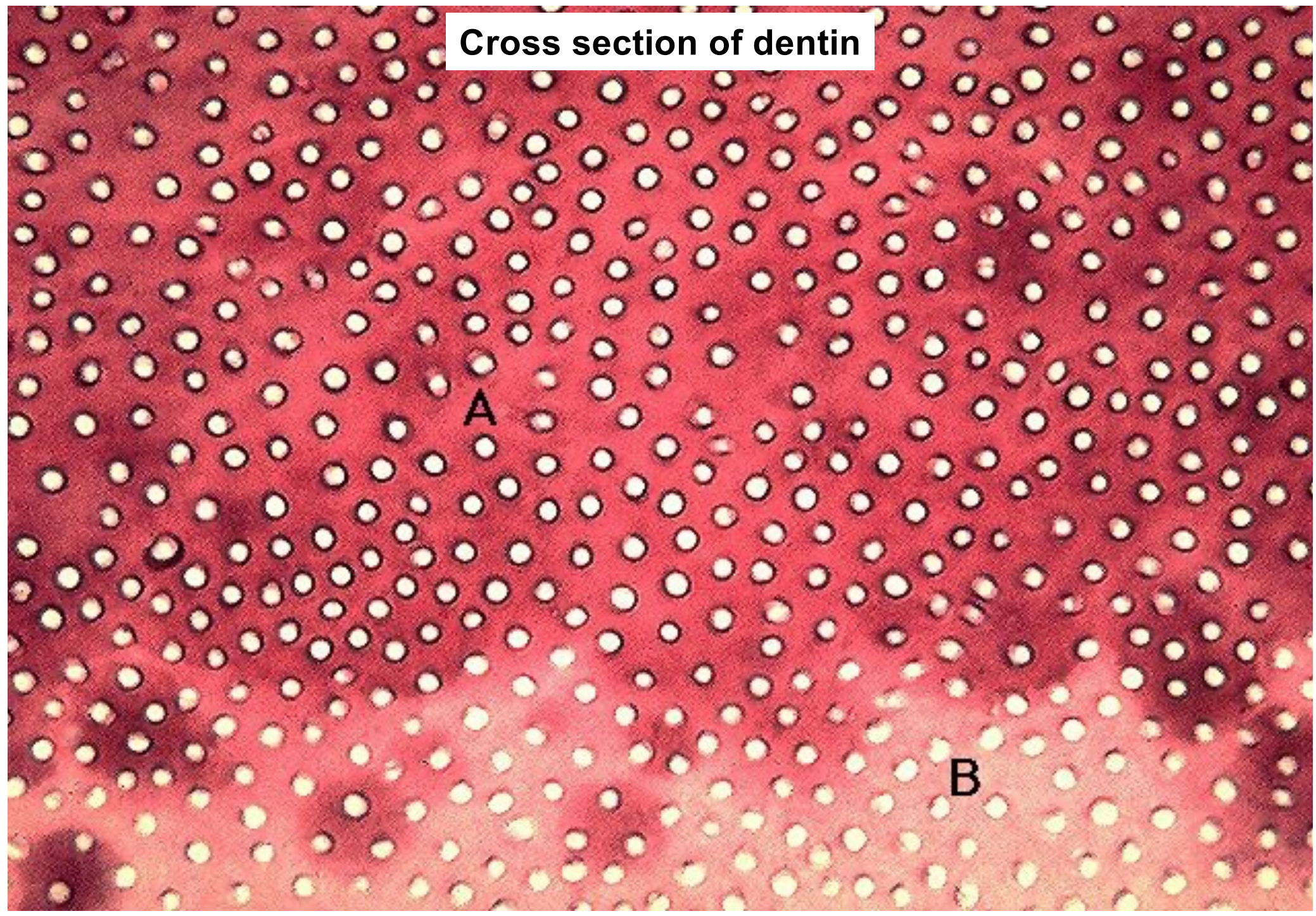
**Odontoblast
process**

**Intertubular
dentin**

**Dentinal
tubules**

**Odontoblast
process**

Cross section of dentin



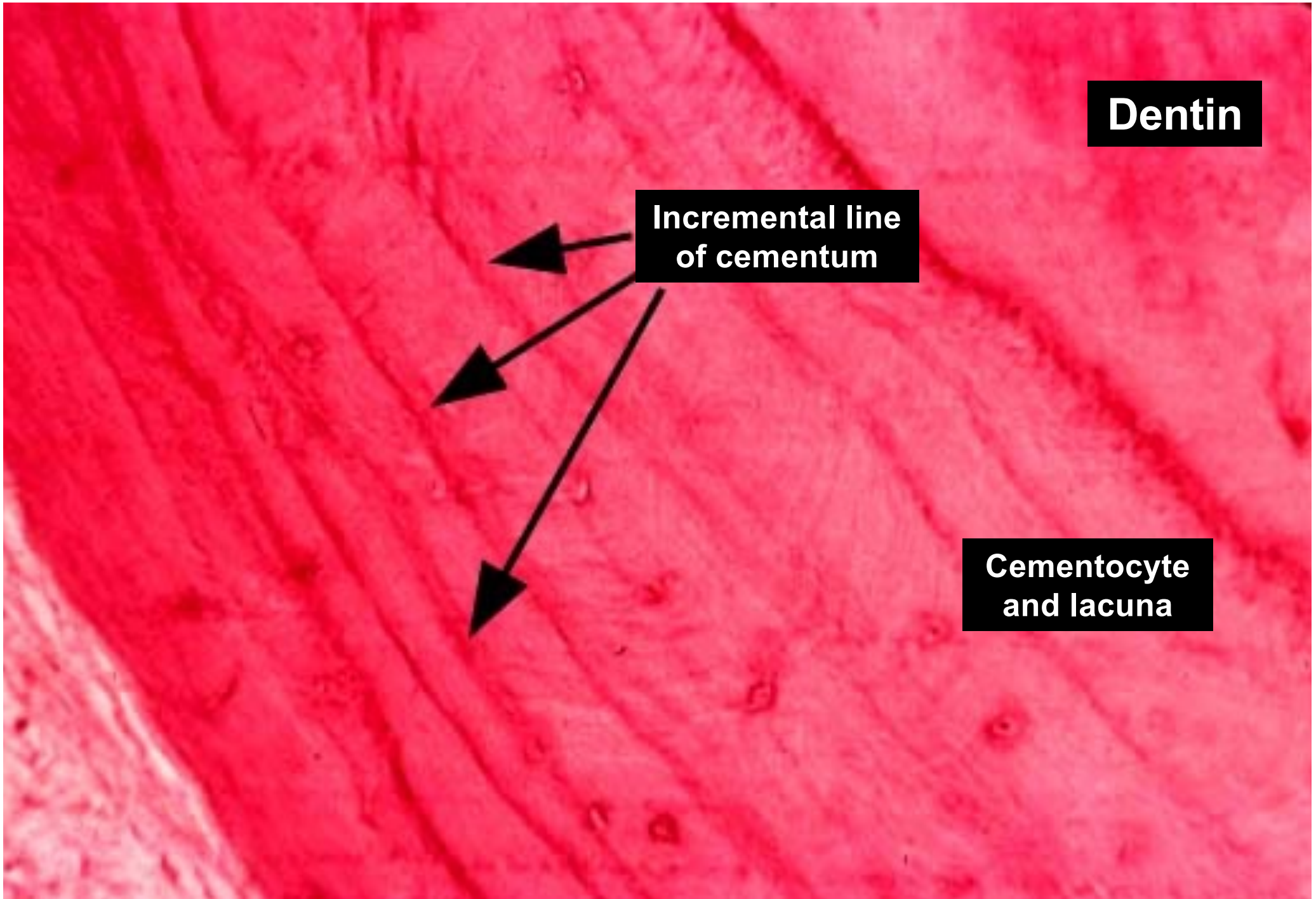
A

B

Dentin

**Incremental line
of cementum**

**Cementocyte
and lacuna**



**Thank you
for
your attention**